

The emerging concern of oral pemphigus vulgaris arising post-COVID-19 infection: A case series

by Rahmi FKG

Submission date: 06-Feb-2024 01:23PM (UTC+0700)

Submission ID: 2287714546

File name: JOMFP-27-557.docx (553.64K)

Word count: 1884

Character count: 11307

1

The emerging concern of oral pemphigus vulgaris arising post-COVID-19 infection: A case series

Indrayadi **Gunardi**, Firstine Kelsi **Hartanto**, Rahmi **Amtha**, Najla **Nadiyah**, Elizabeth Fitriana Sari^{1,2}

Department of Oral Medicine, Faculty of Dentistry, Universitas Trisakti, Jakarta, Indonesia, ¹Dentistry and Oral Health Department, La Trobe University, Rural Health School, Australia, ²Faculty of Dentistry, Universitas Padjadjaran, Bandung, Indonesia

Abstract

Cases of coronavirus disease 2019 (COVID-19) appear with a very diverse pattern of health manifestation, in which the immune system plays a major driver of severe acute respiratory syndrome coronavirus 2 (SARS-CoV-2) infection outcomes. The uncontrolled immune response of SARS-CoV-2 infection could possibly lead to autoimmune diseases, as we observed increased cases of pemphigus vulgaris (PV) post-COVID-19 infection. PV is an autoimmune life-threatening mucocutaneous disease that is very rarely induced by certain drugs or substance. The link between COVID-19 infection and autoimmune diseases is still unknown. This study outline the possible link with PV following infection of COVID-19. A case series of three females and one male between the ages of 33 and 57 with no history of drug-induced illness or allergy were observed in our current case series. All patients previously contracted SARS-CoV-2. The lesions were treated with systemic and oral corticosteroid was given as a basic treatment for PV lesions. Immunomodulator agent was added as an adjunct to reduce the effects of steroid and to decrease the severity of PV. In conclusion, clinicians should be vigilant of the potential emergence of autoimmune reaction following the COVID-19 pandemic. Further investigation is required to unfold the unclear mechanism of PV induced by SARS-CoV-2. We hypothesized that the genetic aberrance inferred by this viral infection might trigger autoimmune diseases and may not limit to PV.

Keywords: Autoimmune diseases, corticosteroid, COVID-19, pemphigus vulgaris, SARS-CoV-2

Address for correspondence: Dr. Rahmi Amtha, Jl. Kyai Tapa No. 260, Grogol, Kec. Grogol petamburan, Kota Jakarta Barat, Daerah Khusus Ibukota, Jakarta 11410, Indonesia.

E-mail: rahmi.amtha@trisakti.ac.id

Submitted: 17-Jul-2023, **Accepted:** 07-Aug-2023, **Published:** 12-Sep-2023

INTRODUCTION

More than 676 million coronavirus disease 2019 (COVID-19) cases were confirmed, and over 6.8 million deaths have been reported worldwide as of April 2023.^[1] The COVID-19 pandemic showed varying degrees of case severity and its damage, which has affected nearly every country in the world. The infection is primarily transmitted through respiratory

droplets and close contact with infected individuals.^[2] The case and fatalities rates of COVID-19 infection are projected as waves, with spikes and then drops over time. Population density, provision of healthcare facilities and public health measurement determined the severity of the pandemic.^[3]

Emerging evidence of PV cases could indicate that COVID-19 may influence the onset of autoimmune

5

Access this article online

Quick Response Code:	Website:
	https://journals.lww.com/JPAT/
	DOI:
	10.4103/jomfp.jomfp_318_23

2 This is an open access journal, and articles are distributed under the terms of the Creative Commons Attribution-NonCommercial-ShareAlike 4.0 license, which allows others to remix, tweak, and build upon the work non-commercially, as long as appropriate credit is given and the new creations are licensed under the identical terms.

For reprints contact: WKHLRPMedknow_reprints@wolterskluwer.com

4
How to cite this article: Gunardi I, Hartanto FK, Amtha R, Nadiyah N, Sari EF. The emerging concern of oral pemphigus vulgaris arising post- COVID- 19 infection: A case series. J Oral Maxillofac Pathol 2023;27:557-61.

diseases.^[4] A systematic review of reported cases revealed that COVID-19 has been linked to a variety of autoimmune diseases, which may shed light on the relationship between autoimmune diseases and this infection.^[5] In addition, a study found that new onset of autoimmune diseases may occur after a diagnosis of positive COVID-19, and the type of immune-related manifestations may be related to the severity of severe acute respiratory syndrome coronavirus 2 (SARS-CoV-2) infection.^[6] The evidence of autoantibodies also found in patients with COVID-19 supported the association between COVID-19 infection and autoimmune diseases.^[7,8] COVID-19 shares some similar clinical manifestations, immune responses and pathogenic mechanisms with some autoimmune diseases, and robust immune responses contribute to the pathogenesis of both diseases.^[5]

Pemphigus vulgaris (PV) is a mucocutaneous autoimmune disease that has manifestation as a widespread bullae and ulceration on skin and mucosa. Several risk factors, including genetics, drugs, viral infection, allergens, and dietary and psychological stress, have been identified as potential triggers of PV,^[9,10] due to the production of autoantibodies against desmoglein-1 and desmoglein-3 in PV resulting in intraepithelial acantholysis and damaging the keratinocyte layer of the epithelium.^[9] Patients with oral PV may experience limited physiological function due to extensive ulceration and prolonged pain.^[11] It is, therefore, crucial to early identify this life-threatening PV in patients with post-COVID-19 infection. This manuscript will outline the emerging cases of oral PV following infection with COVID-19 that would support the link between these diseases.

7

CASE REPORT #1

A 48-year-old woman attended a dental clinic with ulceration that had persisted for two months [Figure 1]. According to the patient's medical history, multiple medications, such as antifungal, antibiotic, antiviral, corticosteroid and antiseptic mouthwash, had been used to treat this ulceration, with no improvement. Her physician confirmed that the patient had been free from COVID-19 infection one month before the onset of oral ulceration. Initial extraoral examination revealed perioral ulceration. Intraoral examination showed extensive ulcerations on the labial, buccal, palatal, tongue and vestibule mucosae. Initially, dexamethasone and co-amoxiclav were administered for seven days. Co-amoxiclav was given with the aim to reduce the risk of other bacterial infections. Vitamin D3 and calcium are also administered as roborant.

After one week, a biopsy was performed on the lower right vestibule to confirm the diagnosis [Figure 2]. With haematoxylin and eosin staining, the histology features showed cleft and acantholysis in the suprabasal epithelium confirming PV. The medication was modified by adding oral methylprednisolone, clobetasol cream and oral azathioprine. In five months, the patient reported that she was completely healed with no lesions remaining. The patient was advised to avoid certain foods such as spicy and fried meals to avoid the recurrence of another ulceration.

7

CASE REPORT #2

A 57-year-old woman presented with oral ulceration that had been occurring for two weeks before visiting dental clinic [Figure 1]. Skin lesions on her breast and trunk appeared several days after oral ulceration. Her past medical history showed that the patient contracted COVID-19 infection five months ago and has no history of allergy to drugs, and other viral infection and systemic diseases were excluded. The patient was managed by oral methylprednisolone and topical suspension of clobetasol-combined dexamethasone. After one month, the adjunct azathioprine was given and continued with lower dose of methylprednisolone. The ulceration was significantly healed with the given treatment after 15 months. We advised them to continue azathioprine and methylprednisolone and tapered off.

CASE REPORT #3

A 56-year-old man presented with oral ulceration that occurred a week before examination [Figure 1]. Following the oral ulceration, a skin lesion appeared on the head. This oral ulceration appeared one month post-recovery from COVID-19 infection. There was no allergic history or any illness noted in the medical records. Oral methylprednisolone and topical clobetasol-combined dexamethasone were administered to treat oral lesions by the oral medicine specialist. The dermatologist confirmed the diagnosis of PV from biopsy on lesion of patient's head. Following this definite diagnosis, the dermatologist administered oral azathioprine and topical clobetasol for the skin lesions.

CASE REPORT #4

A 33-year-old woman complained of oral ulceration for almost one month before examination. The patient was infected with COVID-19 four months prior [Figure 1]. There was no history of allergy, and any systemic and autoimmune diseases. The patient was managed with oral and topical methylprednisolone and showed a significant improvement.

4

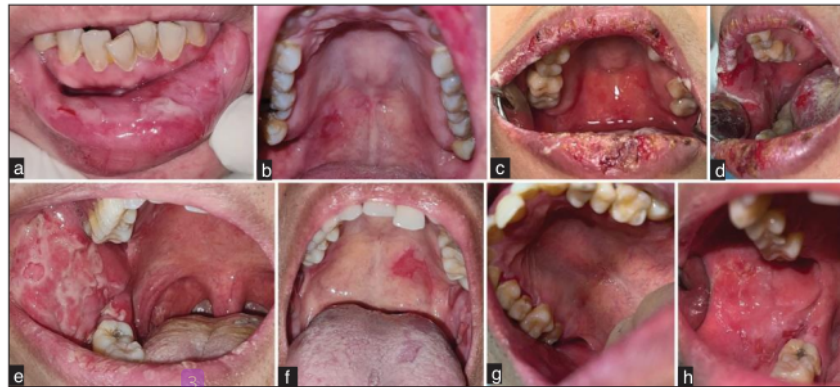


Figure 1 : Clinical presentation of oral PV. Case # 1 (a, b); Case #2 (c, d); Case #3 (e, f); Case #4 (g, h). Courtesy of Prof. Amtha and Dr. Gunardi

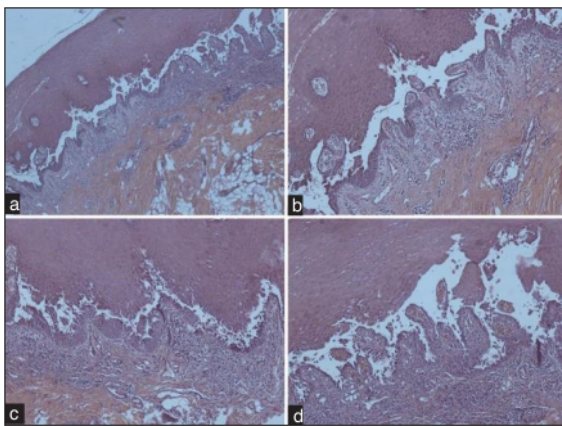


Figure 2: Haematoxylin-eosin staining showed an oral mucosa of stratified parakeratinized epithelium demonstrating suprabasal clefting and acantholysis of the spinosum layers. The sub-epithelium showed dense chronic inflammation. (a) Magnification 40x; (b) magnification 100x; (c) magnification 100x; (d) magnification 200x. Courtesy of Dr. Gunardi and Dr. Hartanto

DISCUSSION

Oral ulceration-associated COVID-19 infection has not yet been specified.^[12-14] The clinical manifestations of COVID-19 infection may resemble ulcerations caused by any oral diseases, especially autoimmune diseases. In addition, patients with history of an autoimmune disease may experience recurrent episodes and severe illness, particularly in PV and oral lichen planus.^[12] In our cases, we presented four patients with oral and skin lesions who were diagnosed with PV, approximately one to five months following COVID-19 infection [Table 1].

Autoimmune diseases are characterized by an abnormal immune response to self- and non-self-antigens.^[15] Currently, more than 80 categories of autoimmune disorders have been identified, but the aetiology of several autoimmune

disorders is not fully understood. Multiple factors, including genetics, age, environment and viral infection, have been proposed. Based on previous publications, herpesvirus,^[16] cytomegalovirus^[16] and varicella zoster^[17] have been implicated as potential predisposing factors for PV. De Medeiros *et al.*^[18] described the first occurrence of PV associated with COVID-19 infection. Several studies were subsequently reported regarding the development of PV after primary SARS-CoV-2 infection or mRNA SARS-CoV-2 vaccination (3–40 days).^[18-21] This virus infection may be a significant environmental factor for those who are genetically predisposed. This is aligned with our PV cases that occurred in the former COVID-19 survivors with no history of allergy or autoimmune diseases [Table 1]. In addition, our cases occurred mostly in female patients and in older patients. Only one case occurred in the early 30's.

The binding of viral spike proteins to cellular receptors is primarily responsible for coronavirus entry into target cells. Angiotensin-converting enzyme 2 (ACE2) has been identified as a key functional receptor of SARS-CoV-2.^[22,23] Xue *et al.*^[24] reported that skin keratinocytes exhibited a high level of ACE2 expression, which makes them a potential coronavirus target. These high levels of ACE2 are also found in the oral mucosa, which may contribute to the development of oral lesions or symptoms.^[25] Our cases demonstrated that all initial lesions appeared on the oral mucosa and were followed by lesions on the skin.

Cross-reactivity with host cells was hypothesized to impair self-tolerance and initiate an autoimmune response to SARS-CoV-2 carriers.^[26-28] The SARS-CoV-2 cross reactivity triggers the development of autoimmune diseases in patients with COVID-19 and the risk of COVID-19 infection in patients with pre-existing autoimmune conditions.^[28]

Table 1: Characteristics of cases of oral PV

	Case #1	Case #2	Case #3	Case #4
Gender, age (y.o)	F, 48	F, 57	M, 56	F, 33
PV occurrence post-COVID-19	1 month	5 months	1 month	4 months
History of autoimmune disease	None	None	None	None
History of allergy	None	None	None	None
Location of initial lesion	Oral	Oral	Oral	Oral
Skin lesion	Perioral	Trunk, breast	Head	None
Treatment	MP, AZA, CLB	MP, CLB-DX, AZA	MP, AZA, CLB-DX	MP
Duration of treatment	Jun–Nov 2022	Jan 2022–April 2023	Nov 2020–Dec 2021	Jan 2023–present
Possible trigger factors of PV post-COVID-19	Food (spicy, fried)	Unknown	Psychological stress	Anxiety

F: female; M: male; COVID-19: coronavirus disease 2019; PV: pemphigus vulgaris; MP: methyl prednisolone; AZA: azathioprine; CLB: clobetasol; DX: dexamethasone

Several pathways, such as molecular mimicry, bystander activation and epitope dissemination, could activate the autoimmunity mechanism triggered by viruses.^[29] In molecular mimicry, the structure of virus antigens and self-antigens is similar. Antigen-presenting cells (APC) will activate T cells, triggering a cross-reactive immune response against both self- and non-self-antigens, thereby causing tissue injury.^[29] In bystander activations, a nonspecific and overreactive antiviral immune response induces a localized pro-inflammatory cytokine environment and the release of self-antigens from damaged tissue. The APC recognizes and presents self-antigen to self-reactive T cells, which lead to tissue injury.^[29] In epitope spreading, persistent viral infections may continue tissue injury and induce the release of more self-antigens and the de novo activation of autoreactive cells, which then target additional self-epitopes.^[29]

The limitation of our serial cases is that all data of COVID-19 infection were based on medical record only. No information regarding the specific type of SARS-CoV-2 virus or the type of COVID-19 drugs consumed by our patients may play a role in the PV development.

CONCLUSION

The emergence of PV or other autoimmune reactions following the COVID-19 pandemic should be suggested as one of COVID-19 infection risk assessments, and oral lesions are most likely to appear before the skin lesions. These important signs in patients with COVID-19 should be observed closely by clinicians as early diagnosis of autoimmune diseases evidently gives a better prognosis for this life-threatening disease. The unclear mechanism of PV induced by SARS-CoV-2 requires further study, although the genetic anomaly caused by COVID-19 infection presumably could play a role in linking this infection with autoimmune disease.

Ethical clearance

All patients have given approval in an informed consent

form regarding the use of their medical records for educational purposes and publication.

Acknowledgment

IG and RA proposed the topic, provided the cases and wrote the manuscript. FK and NN performed the pathology examination. EFS reviewed the manuscript.

Financial support and sponsorship

Nil.

Conflicts of interest

There are no conflicts of interest.

The emerging concern of oral pemphigus vulgaris arising post-COVID-19 infection: A case series

ORIGINALITY REPORT

13%

SIMILARITY INDEX

12%

INTERNET SOURCES

11%

PUBLICATIONS

4%

STUDENT PAPERS

PRIMARY SOURCES

1	pubmed.ncbi.nlm.nih.gov Internet Source	3%
2	Submitted to The University of Texas at Arlington Student Paper	3%
3	www.mdpi.com Internet Source	2%
4	V. Babji, Deepa. "Detection and Comparison of Mutant DNA Sequences in Tissue and Urine Samples of Oral Squamous Cell Carcinoma Patients and Apparently Healthy Individuals", Rajiv Gandhi University of Health Sciences (India), 2023 Publication	1%
5	jrms.mui.ac.ir Internet Source	1%
6	apothesis.lib.hmu.gr Internet Source	1%
7	www.dovepress.com	

Internet Source

1 %

8

C. Cotter, E. Rudd, E. Duarte Williamson, M. Philippidou, A. Tewari. "Anti-Ku positive Juvenile Dermatomyositis", *Clinical and Experimental Dermatology*, 2021

Publication

1 %

9

openaccess.bezmialem.edu.tr

Internet Source

1 %

Exclude quotes On

Exclude matches < 15 words

Exclude bibliography On